



THE COLLEGE OF
OPTOMETRISTS

Stage Two

Overarching case scenario 41

AGE AND GENDER Female, Age 40

ETHNIC BACKGROUND Caucasian

OCCUPATION AND HOBBIES Nurse but on long-term sick leave since vision deteriorated 6 months ago; is going to college to retrain as counselor. Mother to two young children. Gave up driving two years ago.

PRESENTING SYMPTOMS AND HISTORY Increasing difficulty reading and writing (can't keep on lines, can't see end of pen). Macular dystrophy diagnosed 4 years ago, progressive deterioration since. Last sight test by optometrist 10 years ago. Doesn't wear glasses much: seem to make vision worse for reading. Very uncomfortable in bright light outdoors – fashion sunglasses bought don't seem very effective. Can't see the timetable TV screens in local railway station. Registered Sight Impaired/Partially Sighted.

GENERAL HEALTH AND MEDICATION Takes antidepressants.

PRESENT Rx, CENTRATION AND ACUITIES CR39 SV lenses scratched and frame joints wobbly (10 years old)

RE: -2.00/+0.25 x 70 6/54 LE: -1.50DS 6/54 ocd 64

PD/NCD 64/60 at 30cms

VISION RE 6/60 LE 6/60

PINHOLE VISION Could not see through hole

REFRACTION RE -3.00 DS VA 6/36 LE -3.00 DS VA 6/36

Add +4.00 N16 Binoc Add +12.00 N5 Binoc

ACCOMMODATION Not tested

BINOCULAR STATUS Distance cover test with Rx No movement seen
Near cover test with Rx slight exophoria, good recovery

MOTILITY No restriction to any direction; no diplopia reported

CONVERGENCE 10cms

PUPIL REACTIONS PERRLA

FUNDUS EXAMINATION see attached

FIELDS Not done

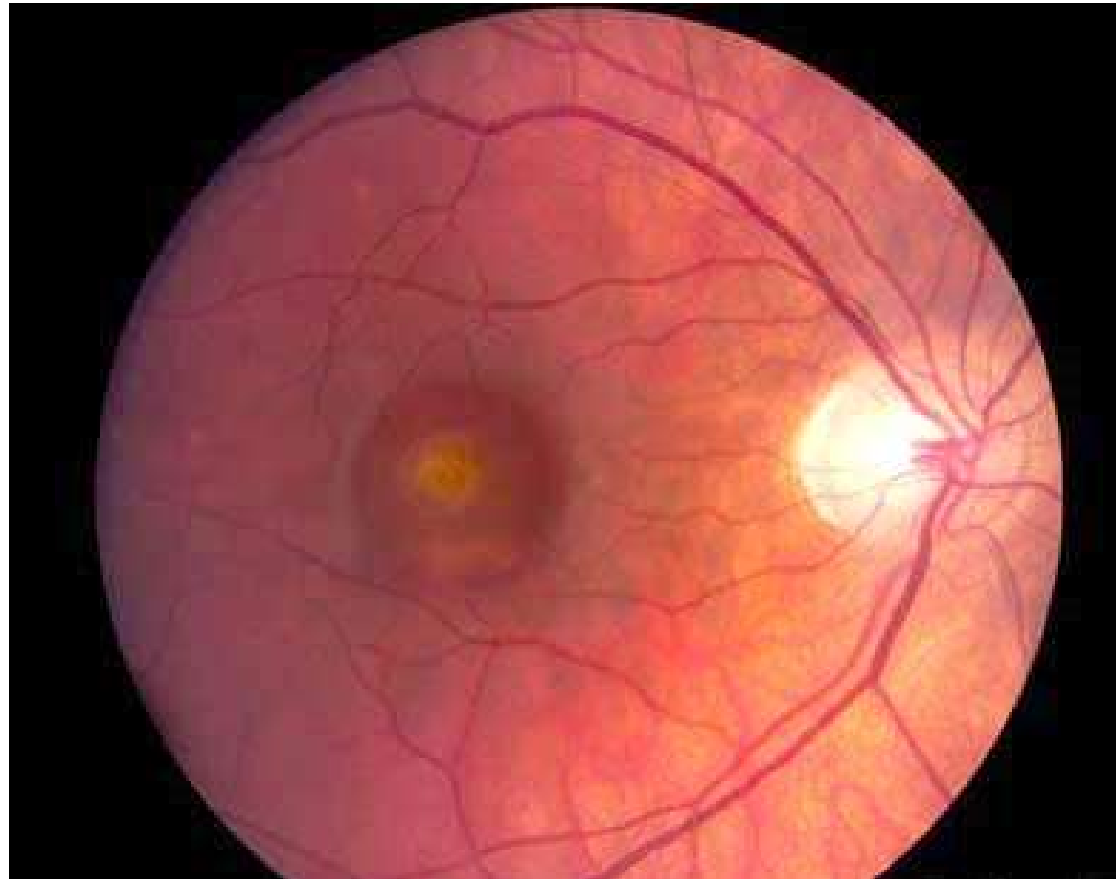
IOP RE 18 mmHg LE 20 mmHg Perkins 10.00am

EXTERNAL EYE EXAMINATION See attached

KERATOMETRY RE 7.80 @ 180 7.80 @ 90 LE 7.80 @ 180 7.75 @ 90

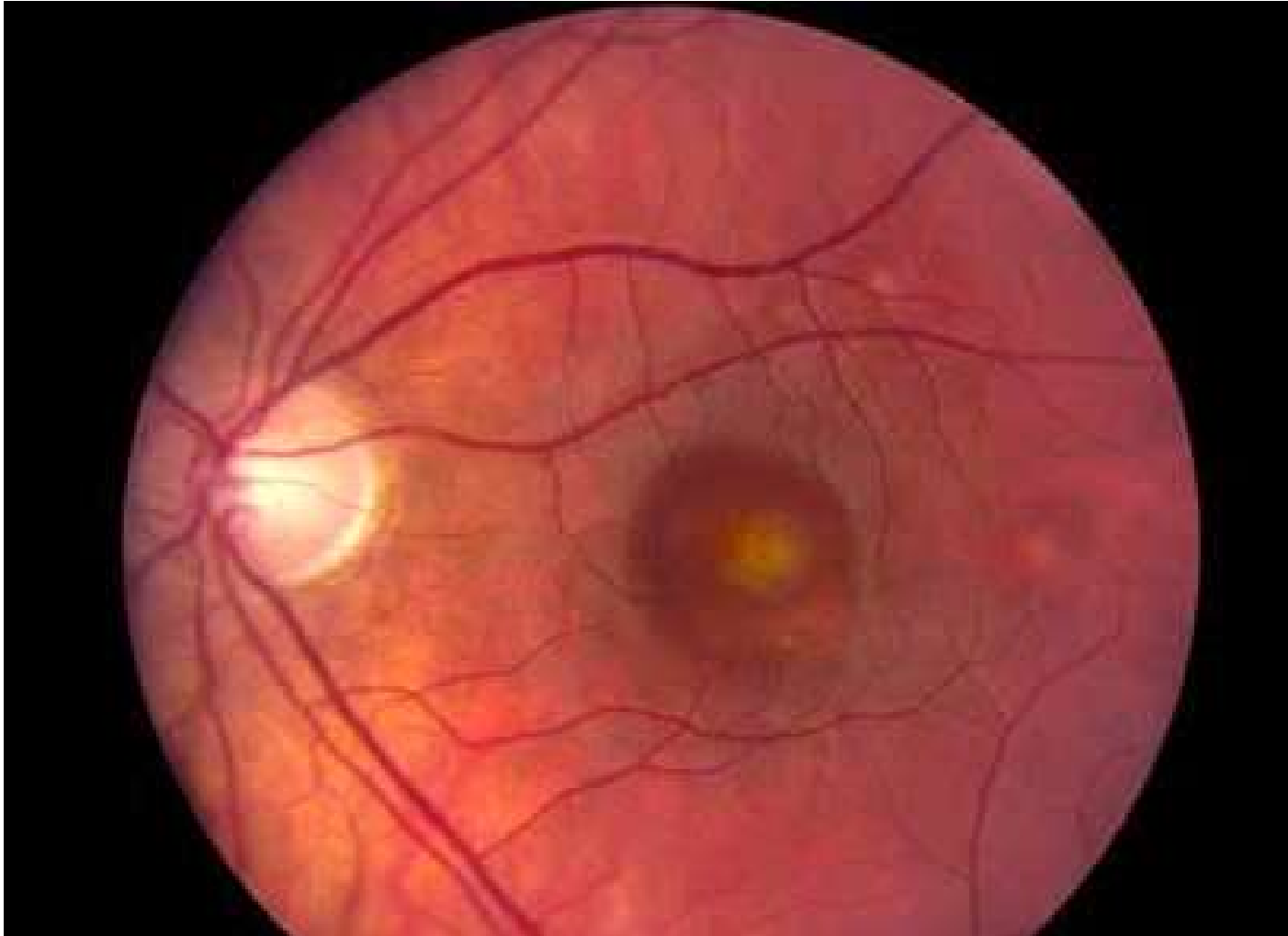
COLOUR VISION reports poor discrimination of similar colours

Fundus RE



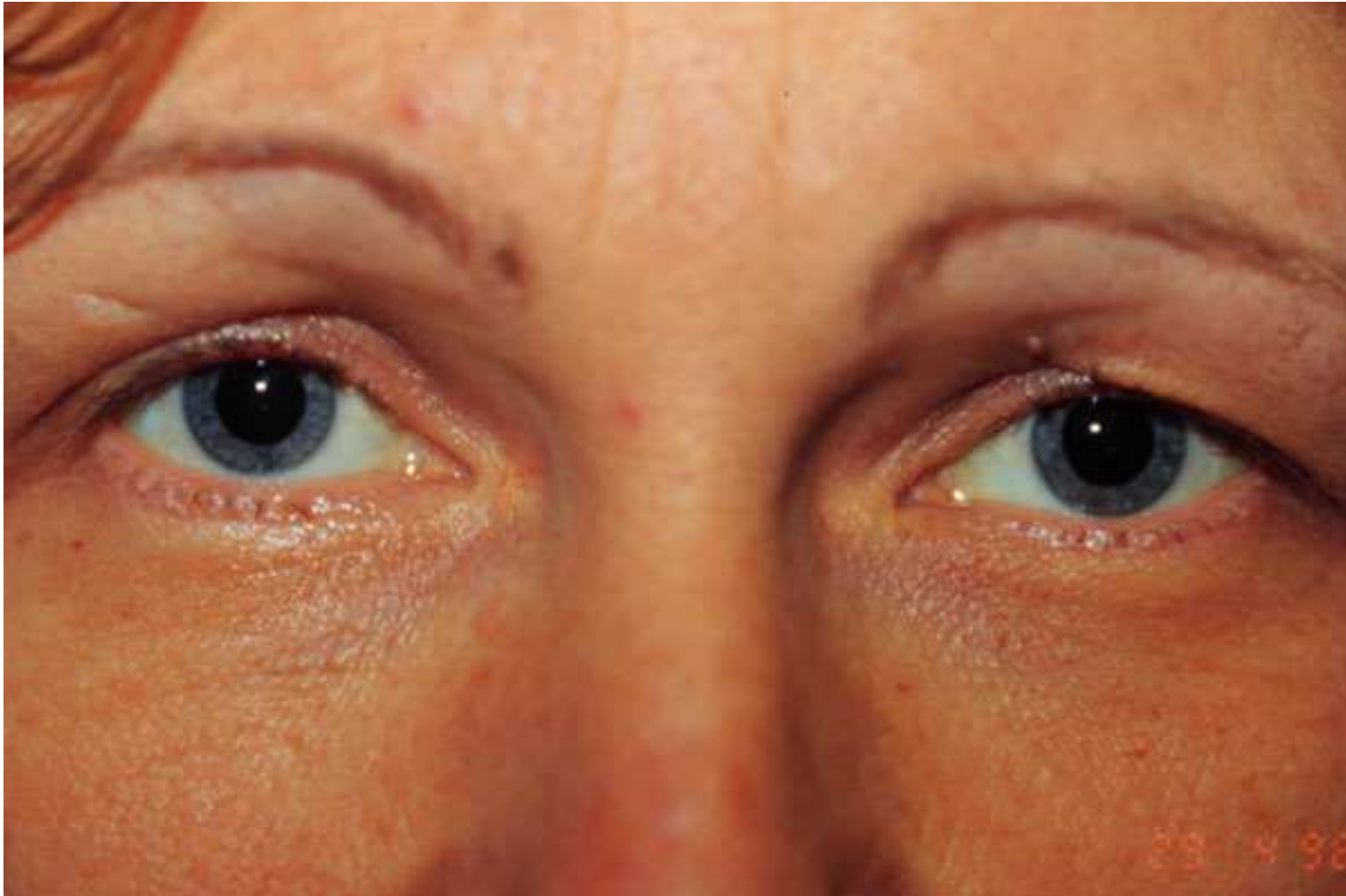R41

Fundus LE



R41

External View



R41